

A STRAIGHT PATH TO DENTAL HEALTH: A COMPREHENSIVE REVIEW OF DENTAL MANAGEMENT IN SCOLIOSIS PATIENTS

Amir Khan Shah

Dental Surgeon, Sardar Begum Dental College, Peshawar, Pakistan

Abstract:

Scoliosis, derived from the Greek word "Skoliosis," denotes a complex spinal condition characterized by lateral curvature and vertebral rotation. This deformity, often manifesting as a three-dimensional deviation, requires a curvature of over 10° on a PA radiograph for classification as scoliosis. Although commonly diagnosed in children, scoliosis can affect individuals across age groups, with a higher prevalence among girls, often attributed to genetic factors. The etiology-based classification of scoliosis assists in identifying underlying causes, and additional classification systems, such as Kings' and Lenke's, facilitate the diagnosis of curve location, degree, and progression. These systems, in conjunction with clinical assessments, measurements, grading, and imaging studies, contribute to accurate diagnosis and treatment planning.

Keywords: Scoliosis, Spinal Deformity, Vertebral Rotation, Diagnosis, Treatment Planning

1. Introduction

Scoliosis is derived from a Greek word "Skoliosis" which means Crooked or bent(1). Scoliosis is a complex condition; it is a deformity of spine that characterizes lateral curvature of spine. This curvature is due to the rotation of vertebrae in one or more segments(2). Sometimes this deviation is not in one plane but a three-dimensional deformity, depending upon the severity and type (1, 3-5). The deviation of more than 10° should be there (on a PA radiograph) for it to be considered under the term of scoliosis (1-3, 5-7). It is mostly diagnosed in children but it can also affect older adults too. It is more prevalent in girls than boys although the exact reason for this is not understood but is strongly linked with genetic inheritance (1, 4, 5, 8). The curvature of spine can be caused by different reasons and that's why to categorize the underlying cause it is generally classified based on its etiologies (6). However, it has several other classification systems such as Kings' classification and Lenke's classification etc. that helps in diagnosing the location of curve, degree of curve and progression of curves. All are used in combination with clinical findings, tests, measurements, gradings and imaging studies for diagnosis and treatment plan (1, 7, 8).

Scoliosis can be classified on the basis of its etiology as; idiopathic, congenital, neuromuscular, and syndrome-related and other secondary reasons (1-4, 9). Among these, the most common and frequent presentation is idiopathic scoliosis, found in otherwise a healthy individual. Idiopathic is further classified into infantile (0-3), juvenile (4-9) and adolescent (10 – up to skeletal maturity) and adult scoliosis which is found in elderly and is the continuation of Adolescent idiopathic scoliosis, or it could be degenerative type, which is due to the development of degenerative changes (1, 5, 7, 10, 11). Congenital scoliosis is

because of developmental defects in spine present at birth (4, 12). Neuromuscular etiologies include cerebral palsy, paralysis, Duchenne muscular dystrophy, spinal amyotrophy, or myelodysplasia.

Other secondary etiologies include syndrome-related scoliosis, such as marfan syndrome, and musculoskeletal disorders such as osteogenesis imperfecta and leg length discrepancy (2, 4). Mild scoliosis is usually less than 20°. Moderate is between 20°-25° and severe is 50° and above (4, 9).

Individuals with scoliosis, whether due to idiopathic or non-idiopathic reasons, often face a number of challenges in their everyday lives including pain, exhaustion (13), trouble finding proper seating postures, and the psychological impact of having a noticeable spinal curve (5, 13). Moderate to severe spinal curves can greatly impact the seating position on a dental chair, leading to poor operator and patient positioning in a dental setting. Poor patient positioning can make it difficult for the operator to provide basic optimal care to the patient (14). Furthermore, patients with scoliosis may find it difficult to sit in a position that does not cause pain and fatigue. When treating a patient, failing to consider proper positioning, increases the risk of intra-operative dental emergencies and can cause problems in the dental settings. Dental emergencies should also be considered because they may be difficult to manage due to improper placement. Therefore, it is essential to have a background knowledge of conditions involving severe spinal curvature and to be mindful of the difficulties that such individuals might present with. Most of such patients when they face difficulties or obstacles during their treatment can neglect their oral health care to the point of exclusion from basic dental services which is violation of any individuals' basic rights. As primary health care professionals, it is our responsibility to make ensure that all our patients receive quality care without being subjected to any form of discrimination (15) For that, it is important to know or have established proper protocols and techniques to not only just treat patients with scoliosis, but also to ensure they receive high-quality oral healthcare.

This aim of this review article is to highlight the significance of having protocols and guidelines in place while treating individuals who have moderate to severe spine curvature. By having the proper protocols, dental professionals can treat patients in a calm and relaxed setting that benefits both the operator and the patient. Through this article we hope to emphasize on the value of having established protocols in our dental community and how important it is to follow them, which will help them in providing treatment to their patients, effectively.

2. Methodology

An integrative review was performed which was done in accordance with Prisma guidelines. For the search, Boolean criteria was used, which was formed using MeSH (Medical subject headings) terms. The criteria formed was:

Scoliosis AND (dental OR oral) AND (treatment OR care OR protocols OR guidelines OR clinic OR management)

Boolean search was conducted on 2/1/23 in three different electronic databases, PubMed, SciELO and Science direct, to identify relevant studies published up to 5th January, 2023. Prisma guidelines were followed (16).

Scrutiny of literature was performed using the following inclusion and exclusion criteria:

2.1 Inclusion Criteria

Open-access articles were included in our research. Articles had to be published in English language to include them. Having a publication date, no later than January 5th, 2023 and focus specifically on management of patients with scoliosis in dental settings, to meet the inclusion criteria. (Table 1)

2.2 Exclusion Criteria

Closed access articles were excluded from our research. Articles that were not published in English language and those that were not specifically related to our topic i.e., management of scoliosis patient in dental settings were also excluded based on the criteria of our research. (Table 1)

Inclusion Criteria	Exclusion Criteria
1) Open-access publications	1) Closed access publications
2) English language	2) Not in English language
3) All publications till 5th January 2023	
4) Publications with information about dental management of patients with Scoliosis	3) Publications not related to dental management of patients with Scoliosis

Table 1 inclusion and exclusion criteria

In preferred reporting items for systematic reviews and meta-analyses protocols (PRISMA-P), as first step, Identification was performed accordingly in which Duplicates were identified using the EndNote X8 software.

3. Results

After performing search across the 3 aforementioned databases, following results were achieved; Science Direct (n = 1000), SciELO (n = 2), PubMed (n = 194). A total of 1196 articles were found. They were then checked for duplicates using Endnote x8 version, as a result, 8 duplicates were found. Consequently, we were left with 1188 articles to screen based on the inclusion and exclusion criteria made. After a thorough screening of titles and abstracts of all the search results, none were found relevant to the criteria formed. Summary of results can be seen in figure 1 below.

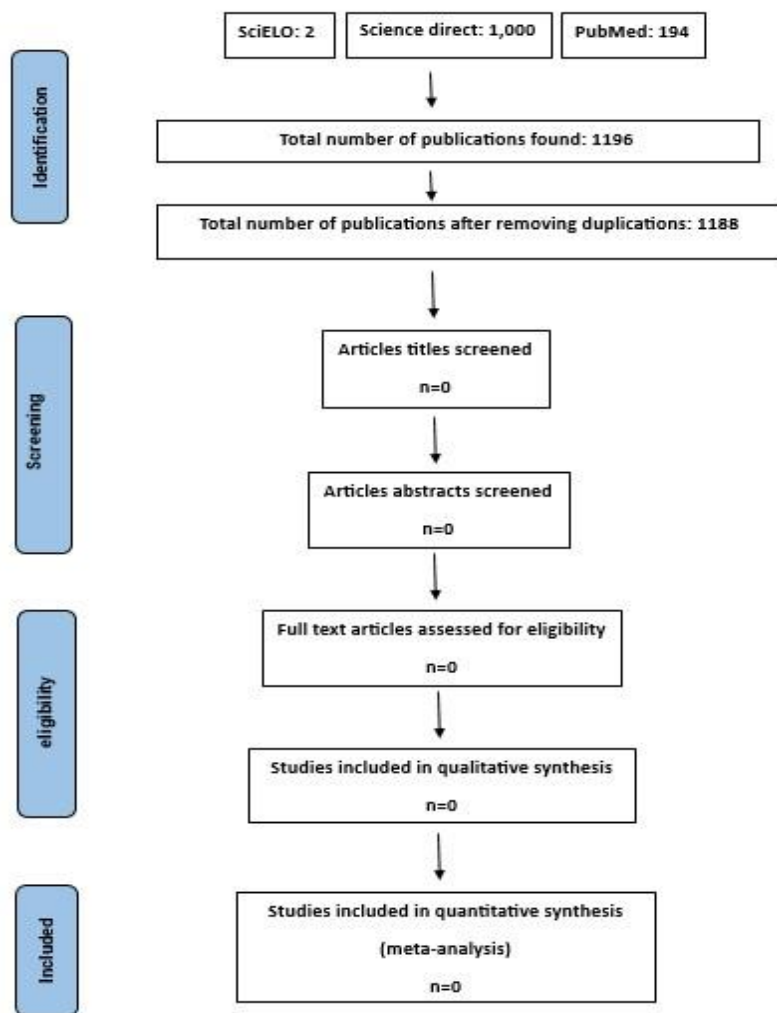


Figure 1 PRISMA flow diagram

4. Discussion

This review article is specifically related to scoliosis patients' positioning and their management in dental office, considering challenges of both the patient receiving the treatment and operator performing the treatment. It is usually preferable to have some basic knowledge regarding scoliosis, scoliosis patients' concerns, and what to expect from them in order to have a better understanding of the challenges.

Scoliosis is basically a deformity in which spinal alignment of an individual gets disturbed, resulting in the lateral spinal curvature. This curvature is 10° in its mild form, 20°-50° in moderate and greater than 50° in severe cases. Deviation can be three dimensional depending upon the severity. It can have many underlying causes, generally classified as idiopathic and non-idiopathic. Scoliosis can be found in an otherwise healthy individual or it can be secondary to another deformity or disorder as well (1-7, 9, 11-13, 17). Because of the spinal curvature, Individuals usually face number of problems in day-to-day life which is similar to back pain that develops after little effort and prolonged durations of sitting upright. They also have this selfconsciousness because of their noticeable vertebral hump. Poor sitting usually occur in moderate-to-severe cases, where we typically see increased curvature (13). And as dental health care professionals, we

recognize the important role that proper positioning of patients on the dental chair plays in treatment and how it is essential for the success of our procedures.

As from the results, the publications which were somehow linked with dentistry and scoliosis were as follows; scoliosis and dental occlusion (18), Adolescent idiopathic scoliosis and rapid palatal expansion (19), factors affecting gingivitis in patient with AIS (20) and the existence of other dental anomalies (overjet, overbite, etc.) associated with scoliosis (18) but as seen in the review and based on our results none specifically talked about the guidelines or management of patients with scoliosis in a dental setup or about the problem faced by scoliosis patients or the difficulties faced by dental operator to treat such patients. Therefore, it is important to emphasize on the need to have such guidelines in place.

Scoliosis patients and their dentists require special protocols during dental procedures due to the uniqueness and complexities they face that comes due to the curvature of spine. There are many challenges which can be either patient-related or dentist-related. Patient-related challenges include persistent uncomfortable positions for prolong periods causing various physical discomforts including pain, fatigue and exhaustion initiating backache intra-operatively leading to stress and anxiety. This also have a psychological impact and can lead to the neglect of further dental treatment by the patient, ultimately affecting their overall health and well-being. Whereas, Dentists can have wide range of difficulties including issues with vision, access, stable patient positioning. These challenges can be more pronounced in cases of severe scoliosis which can make it difficult for the dentist to maintain a comfortable and effective posture during the procedure. This can lead to longer treatment times and negatively impact the outcome of the procedure. Keeping the patient in a supine position can also be uncomfortable and painful without proper cushioning. While standing may be an option for dentists, it can still be difficult for severe cases if access to distal lesions or the distal part of the upper posterior teeth is required and necessary, making the treatment process nervewracking, environment hostile and resulting in poor outcomes. Making accommodations for the patient's comfort is important but if the operator is not at ease, it can trigger cervical or back pain in the dentist themselves who may be cervical pain patients. Such negative outcomes can also be emotionally distressing for dental practitioners themselves. It can give a sense of disappointment and feeling of not provided the best possible treatment to patients. Patients may also feel let down and that they aren't getting the best care available as a result. Furthermore, the difficulties that are associated with the handling and positioning during a dental procedure can also result in an increased risk of intra-operative dental emergencies. These emergencies can be dangerous and distressing for both the patient and the operator and can result in poor management of dental emergencies if proper precautions are not taken. To minimize these risks and ensure the best possible outcomes for patients it is important for operators to be aware of these challenges or to expect these challenges and take steps to minimize the risk of intraoperative emergencies by having proper handling and positioning techniques particularly made to handle such patients in dental offices. It should also be noted that even though scoliosis is not considered a physical disability, many patients who have other physical disabilities and use wheelchairs often complain of discriminatory behavior from dental teams and may feel ignored during discussion. These patients, who use wheel chair, when transferred to dental chair, complained of very poorly adapted chairs according to the needs of patients and caused further discomfort and that they lacked cushion support as well (15). These problems give us insight of what scoliosis patient may also experience.

As reviewed in the results, there is a lack of literature regarding proper protocols and guidelines for scoliosis patient management in dental offices. It is suggested to have guidelines in place related to dental chair positioning of patients with spinal curvature.

There should also be anti-discriminatory policies for such patients. And regarding the adaptation of patient with the dental chair, there should be cushion supports or any other kind of support which can be provided with recommendations of orthopedics. Further research on this topic is needed to make such guidelines. And it is not possible for any single individual to fully understand and address all of the difficulties which are faced by all dental professionals.

It is thus, important to conduct researches to gather information from various practitioners about the specific problems they face and how they tackle such circumstances. This information can be used to provide optimal care while also addressing the challenges. Additionally, it is important to identify possible solutions and strategies that can be implemented in the future to better address these challenges. There should be a multidisciplinary collaboration between dentists and orthopedics to make such protocols or guidelines to better understand the needs and problems related to scoliosis patient and to provide them treatments with quality care, considering both patient and operator factors in order to ensure the best possible outcome for the patient, which is the ultimate aim of this study.

5. Conclusion

In conclusion, this study highlights the lack of guidelines for management of severe scoliosis patients in dental practice. It is important that such guidelines are developed in order to optimize the outcomes for both the patients and their dentists. These guidelines should be made with considerations of dental practitioners and orthopedics point of view. Future researches should focus on creating these guidelines and addressing the short-comings in dental care system for scoliosis patients.

6. References

- Choudhry MN, Ahmad Z, Verma R. Adolescent idiopathic scoliosis. The open orthopaedics journal. 2016;10:143.
- Janicki JA, Alman B. Scoliosis: Review of diagnosis and treatment. Paediatrics & child health. 2007;12(9):771-6.
- Haleem S, Nnadi C. Scoliosis: a review. Paediatrics and Child Health. 2018;28(5):209-17.
- Lee GB, Priefer DT, Priefer R. Scoliosis: Causes and Treatments. Adolescents. 2022;2(2):220-34.
- Trobisch P, Suess O, Schwab F. Idiopathic scoliosis. Deutsches Ärzteblatt International. 2010;107(49):875.
- Qiu Y, Zhu F, Wang B, Yu Y, Zhu Zz, Qian Bp, et al. Clinical etiological classification of scoliosis: report of 1289 cases. Orthopaedic Surgery. 2009;1(1):12-6.
- Yaman O, Dalbayrak S. Idiopathic scoliosis. Turkish neurosurgery. 2014;24(5).
- Ovadia D. Classification of adolescent idiopathic scoliosis (AIS). Journal of children's orthopaedics. 2013;7(1):25-

- LeFever D, Menger RP. Infantile and juvenile scoliosis. StatPearls [Internet]: StatPearls Publishing; 2021.
- Kelly A, Younus A, Lekgwara P. Adult degenerative scoliosis–A literature review. Interdisciplinary Neurosurgery. 2020; 20:100661.
- York PJ, Kim HJ. Degenerative scoliosis. Current Reviews in Musculoskeletal Medicine. 2017; 10(4):547-58.
- Burnei G, Gavrilu S, Vlad C, Georgescu I, Ghita R, Dughilă C, et al. Congenital scoliosis: an up-to-date. Journal of medicine and life. 2015;8(3):388.
- Koop SE. Scoliosis in cerebral palsy. Developmental Medicine & Child Neurology. 2009;51:92-8.
- Mani SA, Mote N, Kathariya M, Pawar KD. Adaptation and development of dental procedure in cerebral palsy. birth. 2015;1:2.
- Rashid-Kandvani F, Nicolau B, Bedos C. Access to dental services for people using a wheelchair. American journal of public health. 2015;105(11):2312-7.
- Page MJ, McKenzie JE, Bossuyt PM, Boutron I, Hoffmann TC, Mulrow CD, et al. The PRISMA 2020 statement: an updated guideline for reporting systematic reviews. International journal of surgery. 2021; 88:105906.
- Lenke LG, Dobbs MB. Management of juvenile idiopathic scoliosis. JBJS. 2007;89(suppl_1):55-63.
- Saccucci M, Tettamanti L, Mummolo S, Polimeni A, Festa F, Salini V, et al. Scoliosis and dental occlusion: a review of the literature. Scoliosis. 2011;6(1):1-15.
- Piancino MG, MacDonald F, Laponte I, Cannavale R, Crincoli V, Dalmaso P. Juvenile/Adolescent Idiopathic Scoliosis and Rapid Palatal Expansion. A Pilot Study. Children. 2021;8(5):362.
- Glowacka J, Opydo-Szymaczek J, Mehr K, Jarzabek-Bielecka G, Glowacki J. Factors affecting puberty gingivitis in Polish girls with adolescent idiopathic scoliosis. Ginekologia polska. 2020;91(3):103-10.