

A COMPREHENSIVE EXAMINATION OF ORAL AND RADIOGRAPHIC FEATURES IN A RARE OSTEOPETROSIS CASE

Abdullah Ali Al-Shahrani and Fatima Mohammed Al-Farraj

Professor, Oral Medicine and Diagnostic Sciences Department, College of Dentistry, King Saud University, Riyadh, Saudi Arabia

Abstract

Osteopetrosis, often referred to as "marble bone disease" or "Albers-Schönberg disease," is a rare hereditary skeletal disorder characterized by a substantial increase in bone density and a reduction in marrow spaces. This condition results from a defect in bone remodeling due to the impaired functioning of osteoclasts, leading to a diminished bone turnover. Osteopetrosis manifests in three primary clinical forms, including a severe malignant infantile autosomal recessive form, an intermediate mild autosomal recessive form, and a benign/adult osteopetrosis with autosomal dominant inheritance. While the latter exhibits fewer symptoms, the first two types have a dismal prognosis, typically manifesting within the first decade of life and leading to early mortality. Infants affected by osteopetrosis may experience a range of clinical symptoms, including impaired hematopoiesis, hepatosplenomegaly, macrocephaly, visual impairment, bone fractures, and hypocalcemia. Although rare, involvement of the endocrine system, except for secondary hyperparathyroidism, has also been reported.

Keywords: Osteopetrosis, Marble Bone Disease, Albers-Schönberg Disease, Hereditary Skeletal Disorder Osteoclast Dysfunction

1. Introduction

The term Osteopetrosis is derived from two Greek words "osteo" meaning bone and "petros" meaning stone. The Osteopetrosis disease is also known as "marble bone disease" (Barry & Ryan, 2003) and "Albers-Schönberg disease", after the German radiologist who was the first to describe the condition as a bone disease in 1904 with an increase in cortical bone mass at the expense of the medullary bone (Waldron, 2002). In 1926, Karshner introduced the term osteopetrosis to describe this disease (Long & Ziccardi, 2001).

Osteopetrosis is a group of rare hereditary skeletal disorders with variable clinical features which are characterized by a marked increase in bone density and reduction of marrow spaces, resulting from a defect in remodeling of bone, caused by the failure of normal osteoclasts to function and consequently resulting in a decrease in bone turnover (Kant et al., 2013). The incidence in infant is 5/1,000,000 live births without any gender predisposition (Diniz et al., 2015).

This disease has been generally reported in three clinical forms: a) severe malignant infantile autosomal recessive inheritance form; b) intermediate mild autosomal recessive form with clinical manifestations similar to malignant form and having the lowest incidence rate; and c) benign/adult osteopetrosis with autosomal dominant inheritance

and with fewer symptoms. The prognosis of the first two types is very poor and is characterized by an early onset, usually within the first decade of life, and early death. Affected infants can exhibit a wide spectrum of clinical symptoms including impaired hematopoiesis, hepatosplenomegaly, characteristic macrocephaly, visual impairment, bone fractures and hypocalcaemia. With the exception of secondary hyperparathyroidism, involvement of the endocrine system seems to be quite rare (Diniz et al., 2015).

The third benign-type is characterized by a later onset and a longer life span (Kant et al., 2013). Adult Osteopetrosis may clinically exist in two major variants. In Type I, cranial nerve compression is a predominant feature and in Type II, skeletal fractures occur more frequently than nerve compression (Ambika et al., 2010). Most forms are characterized by a decreased vascularity of the involved bones that predisposes the patient to the development of osteomyelitis. Osteomyelitis may occur as a complication to odontogenic infections caused by tooth extraction or pulpal necrosis in almost 10% of the cases (Ambika et al., 2010). Osteomyelitis secondary to osteopetrosis is more common in the mandible than in the maxilla due to thin cortical bone and a rich collateral blood supply to the maxilla (Sharma et al., 2013; Garcí'a et al., 2013). The leading cause of the increased rate of infection is thought to be a lack of adequate bone vasculature (Ambika et al., 2010).

As a consequence, the present rare hereditary bone disease known as Osteopetrosis in a 27 years old young female will be presented to increase the awareness of the dentists to the relevance of such rare conditions and the importance of their dental management.

2. Case Report

A 27 year old Syrian female diagnosed with osteopetrosis was sent to our clinic by her physician for regular dental check-up. On taking the medical history from the patient, the patient informed us that the disease was noticed 2 years ago when the size of the head and mandible started to increase as well as her foot size, in addition to blurring of her vision especially in the left eye. The patient was not aware of any genetic or previous incidence of any of her family members having her condition to relate it as a familial hereditary disease.

Our clinical and radiographic examination, confirmed the pervious diagnosis of Osteopetrosis: a rare hereditary bone disease. The patient was complaining of pain in the temporomandibular joint (TMJ) area. During TMJ examination, there was tenderness on palpation of the TMJ area. High occlusal pressure was detected on the teeth with 2 mm over jet and 3 mm overbite having numbness along the mandibular border of her chin. After proper intra oral screening, there were extensive bone out growths in the maxillary and mandibular arches. The clinical picture showed overall increase in amount of bone from the facial, palatal and lingual aspects with apparent spaces between the teeth due to continuous bone growth but without apparent periodontal disease [Figures 1a, 1b and 1c].

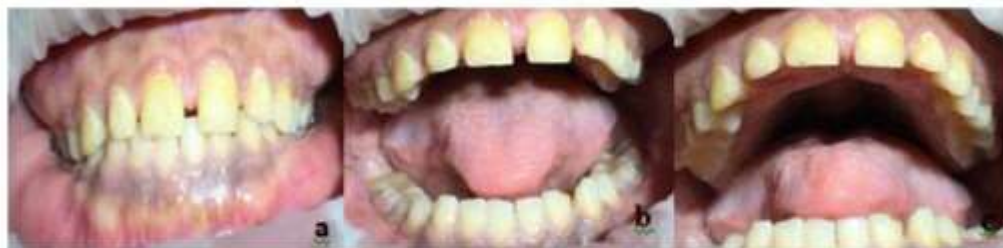

Figure 1 (a, b &c): Intraoral photographs showing dental and alveolar bone status

On panoramic radiograph, the morphology of the roots was obscured due to the presence of a generalized increase in bone density of both the maxillary and mandibular arches with lack of a distinct lamina dura around the teeth. Narrowing of the inferior alveolar nerve canal was observed. Fracture of the mandible was also noted on the left side between the roots of the premolar area, with no evidence of osteomyelitis [Figure 2]. and mandibular jaws and area of fracture (white arrow)

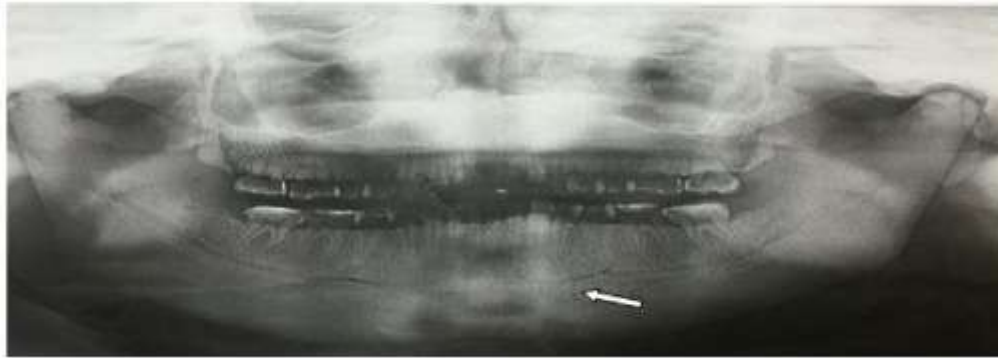


Figure 2 : Panoramic radiograph showing the bony growths of the maxillary

As part of treatment to prevent further complications, a night guard was provided for the patient to relief the pain and reduce the inflammation and tenderness in the TMJ area (figures 3, 4).



Figure 3 : Photograph showing cast of the patient



Figure 4 : Photograph showing constructed night guard

After 3 months, the patient was recalled to the dental clinic for follow up. On clinical examination, the pain in the TMJ area was relieved following the regular use of the night guard by the patient, but there was some increase in the density of the bone size in the lower molar area. Additionally, the patient came with fractured disto-incisal angle of the upper left central incisor [tooth #21] (Figure 5).

The tooth was restored with composite dental restoration after smoothing of the sharp edges, etching and bonding without exposing the patient to local anesthesia. After completing the restorative procedure, prophylactic treatment was carried out to improve oral hygiene (figure 6).

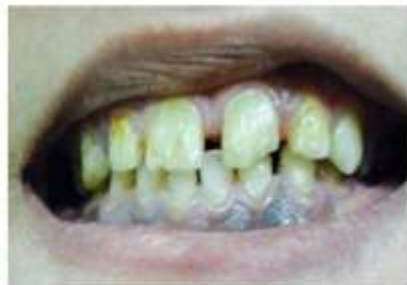

Figure 5: Intra oral photograph showing disto-incisal angle fracture of tooth #21

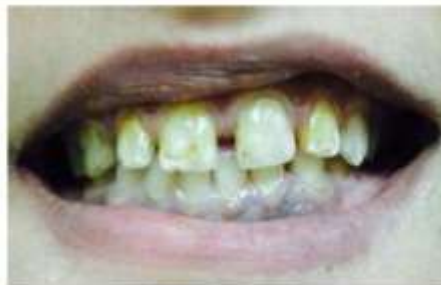

Figure 6: Intra oral photograph showing restoration of tooth #21

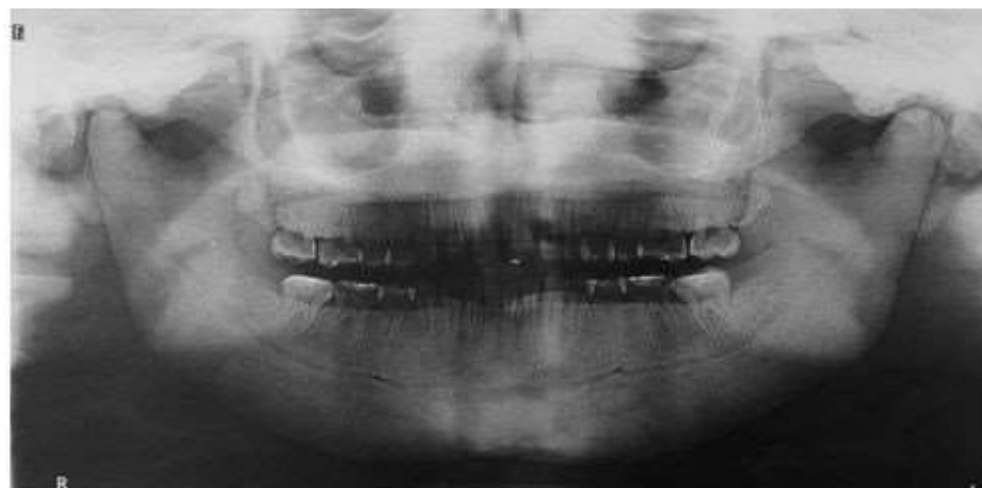

Figure 7: 3 months follow up panoramic radiograph

The patient was instructed to continue using the night guard on a daily basis to improve the muscular spasm and strain falling upon the TMJ and in turn to relieve the TMJ pain. And additionally, to improve her oral hygiene by regular brushing of her teeth twice a day and the use of mouth washes as she developed a new habit of smoking to relieve her stress. A recent panoramic radiograph was taken for follow up as shown in figure 7.

3. Discussion

Adult Osteopetrosis is usually discovered later in life than the infantile form and exhibits less severe manifestations (Waldron, 2002). It is diagnosed at the third or fourth decade of life by means of routine roentgenograms. It is usually inherited as an autosomal dominant trait. Mostly, the axial skeleton is involved. The two forms of Adult Osteopetrosis may be differentiated by clinical and radiological signs. Autosomal Dominant Osteopetrosis (ADO) type I is characterized by a pronounced and symmetrical osteosclerosis of the skull and an enlarged thickness of the cranial vault. Clinically, ADO type I is the only type of osteopetrosis not associated with increased fracture rate (García et al., 2013). Less sclerosis of the skull was found in type II (Albers-Schöberg disease) and it was more pronounced in the base. Clinical manifestations of ADO type II are dominated by long-bone fractures, which occur, with or without trauma, in 78% of the patients. Other classic manifestations of ADO type II include hip osteoarthritis, facial nerve palsy, and mandibular osteomyelitis (Barry & Ryan, 2003).

In the present case, the patient had no signs of Osteopetrosis at birth or in early infancy. There was no history of recurrent bone fractures, auditory disturbances or facial palsy but the patient had started to develop blurring visual disturbances. Facial deformity was not clinically apparent. On oral examination, no delayed tooth eruption or early

tooth loss was observed nor were there any impacted, malformed teeth. The inferior alveolar canal appeared narrowed in the radiograph. The patient had signs of paresthesia and numbness, in particular along the mandibular border of her chin with thickening of the adjacent soft tissue and muscle.

Ambika et al. (2010) confirmed that radiographic examination plays a vital role in the diagnosis of Osteopetrosis. They stated that increased radiopacity of the entire skeleton result in diffuse, homogenous and sclerotic bones. The normal trabecular pattern may not be visualized due to excessive bone density (García et al., 2013). The osteopetrosis is a rare hereditary bone disease. The estimated incidence of this disease is 1 among 100,000 to 500,000 people. It is characterized by malfunction of osteoclast cells and impaired bone resorption (Makarem et al., 2012).

In healthy bone, a steady state is achieved in which the bone formation by osteoblasts is balanced by bone resorption by osteoclasts. Dysfunctional osteoclasts that are observed in Osteopetrosis result in bony over growth, leading to bones that are abnormally dense and brittle. It is believed that osteoclasts fail to release the necessary lysosomal enzymes for bone resorption into the extracellular space (Kant et al., 2013).

As mentioned earlier in the present case, there is fracture of the mandible on the left side between the roots of the premolar area, with no evidence of osteomyelitis. Patient with osteopetrosis have high risk for fracture and infection (Makarem et al., 2012). Dental abnormalities may be attributed to the pathological changes in Osteopetrosis. Patients with the disease seem to be especially susceptible to osteomyelitis (Ahmad et al., 2006).

Osteomyelitis is a well-described complication of osteopetrosis. The mandible is mostly affected because of the impaired white cell function and reduced vascular supply and these have been considered as key factors associated with its development (Trivellato et al., 2009). Cases were reported related to osteomyelitis that arose secondary to osteopetrosis in patient's following extraction of maxillary right molars and stated that the site of extraction did not heal even after taking repeated courses of antibiotics. Pus discharge was present extra orally and the intra oral examination revealed a mucosal defect in the right maxillary molar region, with exposed necrotic bone extending up to the maxillary tuberosity (García et al., 2013).

Possible related dental complication may include enamel hypoplasia with malformation in enamel and short roots. There are also reports of difficulty to detect the pulp chamber of the tooth in dental radiographs because of the increased bone density (Makarem et al., 2012). In contra distinction to the clinical and radiographic findings where the patient exhibited a good oral hygiene with absence of any carious lesions and calculus deposition. Makarem et al. (2012) reported a case with similar occlusal pattern with severe overjet of the anterior teeth and severe bilateral cross bite in posterior area. in consistency to the findings in our patient who had around 2mm overjet and 3mm overbite but without any cross bite in the posterior teeth. Differential diagnosis of the disease that should be taken into consideration may include Van Buchem disease, autosomal dominant osteosclerosis, such as endosteal hyperostosis of the Worth type and sclerosteosis (Lam et al., 2007).

improvement (Makarem et al., 2012). The prognosis of the infantile osteopetrosis without therapy is usually poor and most of those infants fail to thrive and die within their first decade of life (Lam et al., 2007).

In reported cases related to type II autosomal dominant osteopetrosis, supra gingival and sub gingival scaling along with root planning is performed. Patients are also advised to rinse their mouth with 0.2% chlorhexidine gluconate mouth wash twice daily and topical fluoride application. On regular follow-up visits every 6 months, the patient showed no evidence of fractures and osteomyelitis affecting any bone, no signs of cranial nerve involvement and no dental caries and abscesses (Kant et al., 2013).

4. Prognosis

- The present reported case is a benign/adult type of osteopetrosis based on the history with autosomal dominant inheritance.
- There are no effective medical treatment for osteopetrosis to this date.

- In relation to the present case, the best therapeutic approach for this patient was preventive management and maintenance of good oral hygiene by regular brushing of her teeth twice a day and intake of a balanced diet and was advised to reduce the amount of sugar and carbohydrate to prevent dental caries from occurrence .

Conflict of Interests:

The authors declare that they have no conflict of interests.

Patient Consent:

According to the regulation of King Saud University hospital, the patient consent and permission was taken to use her clinical and radiographic photographs' for publication.

5. References

- Ahmad, I., Abbas, S.Z., Haque, F., Rashid, M., & Ahmad, S.A. (2006). Osteomyelitis of mandible-a rare presentation of osteopetrosis. *Indian J Radiol Imaging*, 16, 253-256.
- Ambika, G., Shikha, K., Premdeep, G., & Virendra, S. (2010). Maxillary osteomyelitis secondary to osteopetrosis – a rare Case report. *J Clin Diagn Res*, 4, 3261-3265.
- Barry, C.P., & Ryan, C.D. (2003). Osteomyelitis of the maxilla secondary to osteopetrosis: report of a case. *Oral Surg Oral Med Oral Pathol Oral Radiol Endod*, 95, 12-15.
- Diniz, G., Olukman, O., Calkavur, S., Buyukinan, M., & Altay, C. (2015). A Histologically Diagnosed Case with Infantile Osteopetrosis Complicated by Hypopituitarism. *Case Rep Pathol*, 2015, 786836. doi: 10.1155/2015/786836.
- García, C.M., García, M.A., García, R.G., & Gil, F.M. (2013). Osteomyelitis of the Mandible in a patient with osteopetrosis. Case report and review of the Literature. *J Maxillofac Oral Surg*, 12, 94-99.
- Kant, P., Sharda, N., & Bhowate, R.R. (2013). Clinical and Radiological Findings of Autosomal Dominant Osteopetrosis Type II: A Case Report. *Case Rep Dent*, 2013, 707343. <http://dx.doi.org/10.1155/2013/707343>
- Lam, D.K., Sándor, G.K., Holmes, H.I., Carmichael, R.P., & Clokie, C.M. (2007). Marble bone disease: a review of osteopetrosis and its oral health implications for dentists. *J Can Dent Assoc.*, 73, 839-843.
- Long, R.G., & Ziccardi, V.B. (2001). Osteopetrosis of the maxilla. *Oral Surg Oral Med Oral Pathol Oral Radiol Endod*, 91, 139-140.
- Makarem, A., Lotfi, N., Danesh-Sani, S.A., & Nazifi, S. (2012). Osteopetrosis: Oral and Maxillofacial Manifestations. *Int J Head Neck Surg*, 3, 115-117.
- Sharma, S.S., Saravanan, C., Sathyabama, V., & Satish, C. (2013). Osteopetrosis of the mandible masquerading as tubercular osteomyelitis. *BMJ Case Reports*, Jan (10), 2013. doi: 10.1136/bcr-2012-007487.
- Trivellato, A.E., Ribeiro, M.C., Sverzut, C.E., Bonucci, E., Nanci, A., & de-Oliveira P.T. (2009). Osteopetrosis complicated by osteomyelitis of the maxilla and mandible: light and electron microscopic findings. *Head Neck Pathol*, 3, 320-326.

Waldron, C.A. (2016). Bone Pathology. In: Neville BW, Damm DD, Allen CM, Chi A. C., editors. Oral and Maxillofacial Pathology. (4th ed.) Philadelphia: Saunders, Chapter 14, 574-576.